

Surgical Treatment Results in Tibia Pilon Fractures : About 32 Cases

Zied Mansi ^{a*}, Abdelkader Tounsi ^a, Ltifi Atef ^a,
Islem Chneti ^a, Hedi Rbai ^a, Wajdi Chermiti ^b, Ali Haggui ^c,
Bacem Zaidi ^d and Wael Gazzah ^e

^a Department of Orthopaedic Surgery, IBN EL Jazzar KAIROUAN University Hospital, Kairouan 3100, Tunisia.

^b Department of Orthopedic Surgery, SAHLOUL University Hospital, Sousse, Tunisia.

^c Department of Orthopedic Surgery, Hospital of Kasserine, Kasserine, Tunisia.

^d Department of General Surgery, IBN EL Jazzar University Hospital, Kairouan 3100, Tunisia.

^e Department of Urology, IBN EL Jazzar University Hospital, Kairouan 3100, Tunisia.

Authors' contributions

This work was carried out in collaboration among all authors. All authors read and approved the final manuscript.

Article Information

DOI: <https://doi.org/10.56557/jocrims/2024/v10i19026>

Open Peer Review History:

This journal follows the Advanced Open Peer Review policy. Identity of the Reviewers, Editor(s) and additional Reviewers, peer review comments, different versions of the manuscript, comments of the editors, etc are available here:

<https://prh.ikpress.org/review-history/12628>

Original Research Article

Received: 20/10/2024

Accepted: 23/12/2024

Published: 29/12/2024

ABSTRACT

The Study carried out a retrospective study of a series of 32 cases of tibial pilon fractures, treated surgically in the traumatology-orthopedics department of the IBN EL JAZZAR Hospital in KAIROUAN, over a period of 8 years from January 2014. to December 2021.

The fracture of the tibial pilon affects young active subjects, with an average age of 42 years, and a male predominance, the sex ratio M/F equal to 2.2 The common causes of high energy trauma were : fall from height 47 % followed by public road accidents at 31.25%. Anteroposterior view and

*Corresponding author: E-mail: doc.zm@hotmail.fr;

lateral x-rays of the ankle we use ankle series to confirm the diagnosis; AP, Lateral and Mortise view to confirm the diagnosis, and to analyze the different morphology of the fracture. Surgical treatment by open osteosynthesis was carried out in 65% of cases; combined treatment means; and closed treatment in 11% of cases. According to SOFCOT clinical criteria, functional results were good in 65% of cases, average in 25% of cases, and poor in 10% of cases. The analysis of our results showed a majority of good clinical and radiological functional results with open treatment: which showed its superiority compared to closed treatment; and combined treatment. Complications noted were infection; skin necrosis; algodystrophy.

Keywords: Tibial pestle-osteosynthesis; bone lesions; bone fracture.

1. INTRODUCTION

Fractures of the tibial pilon represent 3 to 10% of all tibial fractures. They arise from high-energy trauma by axial compression. They are serious given: their complexities, their therapeutic difficulties and the absence of muscular coverage with vascularization, making the prognosis severe dominated by the risk of skin necrosis, infection, malunion, pseudarthrosis and osteoarthritis [1].

The development of anatomical implants with angular stability and the recent improvement in the definition of surgical approaches have clearly changed the prognosis of fractures.

2. MATERIALS AND METHODS

This is a retrospective study, on 32 cases of tibial pilon fractures treated surgically, within the orthopedic traumatology department of the IBN EL JAZZAR Hospital in KAIROUAN over a period of 8 years, from January 1, 2014 to December 31 2021.

Through 450 ankle traumas collected at the orthopedic traumatology department of the IBN EL JAZZAR Hospital in KAIROUAN over the same study period, we noted a number of 54 fractures of the tibial pilon, or 12% of ankle fractures. The population most exposed in our study was the young and active population. With an average age of 37 for men, and 41 for women. with a clear male predominance with 22 men or 68% and 10 women or 32% with a sex ratio of 2.2. The left side was affected in 60%.

Concerning the etiologies we noted: Falls from a high place in 46.87%, AVP came second with a percentage of 31.25%, Sports accidents were less frequent than in 15.62%. Assaults in only 6.25% of cases.

In our study, we noted a clear predominance of the indirect mechanism (59%) in the occurrence of tibial pilon fractures.

Clinically, we grouped 14 open fractures, or 22%; including 7 type I cases, 5 cases classified as type II, and 2 cases classified as type III.

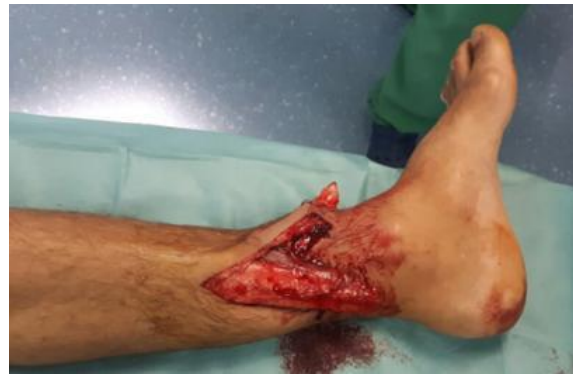

Fig. 1. Clinical image showing an open fracture of the left tibial pilon.

The assessment includes standard x-ray images of the ankle in frontal and lateral view, centered on the ankle. The profile must include the entire rearfoot and calcaneus. These two images make it possible to diagnose bone lesions according to the SOFCOT classification [2].

Table 1. Distribution of incomplete fractures

Type of fracture		Effective	Percentage
Marginal anterior	with acute articular trait	5	9.375%
	with multiple articular lines	2	3.125%
Posterior marginal		2	3.125%
Sagittal		2	3.125%
Sipiroid of the tibia irradiated to the tibial pilon		24	43.75%

Table 2. Distribution of tibial pilon fractures according to the SOFCOT classification

Type of fracture	Percentage
Complete fracture	59.38%
Incomplete fracture	40.63%

Table 3. Distribution according to the approaches used

Look first	Number of cases	Percentage
Anteromedial premalleolar	5	9.375%
Anterolateral	4	6.25%
Previous	2	3.125%
Medial	29	56.25%
Lateral for fibula	2	3.125%
Double approach (internal/external)	12	21.875%

In our study, all our patients systematically benefit from CT imaging.

subluxation is often associated with tibial pilon fractures.

In our study, due to their therapeutic and prognostic implication, bone lesions were analyzed and listed according to the SOFOCOT classification [3].

In our study, 7 patients presented with a tibial-talar dislocation, i.e. 12.5% of cases.

17 patients presented with osteochondral depression.

According to the SOFOCOT [3] classification of tibial pilon fractures, in our study, we noted the predominance of complete articular fractures in 32 cases or 59,38%, then incomplete fractures come in 22 fractures or 40,63% of cases

Therapeutically All our patients benefited from surgical treatment:

Depending on the intensity of the trauma and the point of impact, talocrural dislocation or

Approaches first: In our series, the internal approach was more frequently used in 18 cases or 56.25%, then the double approach (internal/external) with a rate of 21.875%.

2.1 Distribution of Therapeutic Fixation Modalities

a. Internal fixation

Table 4. Distribution according to therapeutic modalities

	Technical terms	Number of cases	Percentage	
Target plate	Isolated	36	68.75%	
	Associate	Epiphyseal screwing	5	9.375%
		Epiphyseal pinning	2	3.125%
Screwing	Simple	7	12.5%	
	Associated with a pinout	4	6.25%	

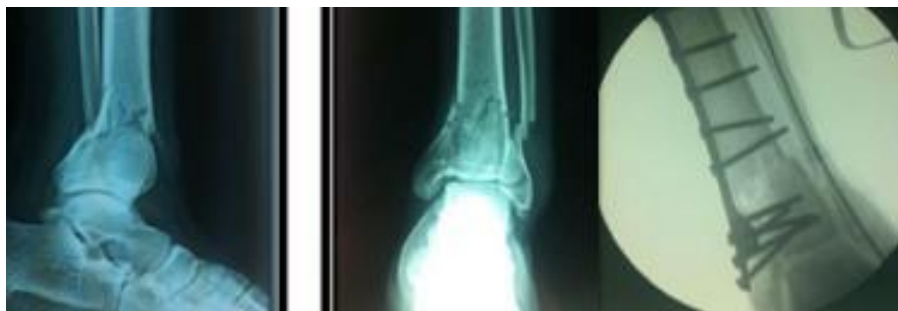

Fig. 2. (Ankle AP and lateral) a complex fracture of the tibial pilon treated with a trefoil plate with pinning of the fibula.

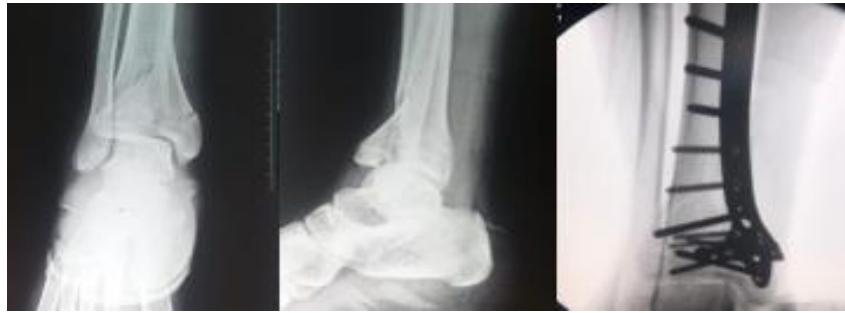

Fig. 3. A complex fracture of the tibial pilon treated with a trefoil plate

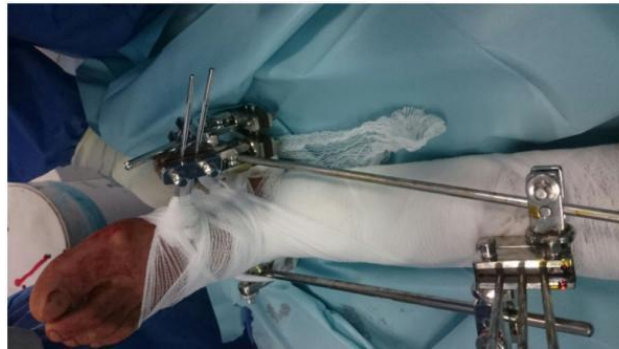

Fig. 4. Clinical image showing a Hoffman external fixator assembly

b. External fixation

In our study, the external fixator was used in 4 cases.

c. Postoperative complications

In our series, 7 patients presented complications, or 12.5% of cases.

- Infection was noted in 4 patients
- Skin necrosis was seen in 3 cases:

2 cases limited to one centimeter not exposing the osteosynthesis material in which the was good.

1 case exceeded one centimeter and exposed the osteosynthesis material, which was treated with a fasciocutaneous rotation flap.

3. RESULTS

The patients were reviewed with a mean follow-up of 2 years and 3 months with extremes of 10 months and 4 years. The results were assessed, according to the SOFCOT 1991 score [2].

They were obtained according to the clinical evaluation criteria defined by Biga Sofcot [2]

which we adapted to the fractures in our study, without taking into account the type of treatment.

Table 5. Results according to Biga Sofcot criteria

Results	Percentage
Excellent	21%
Good	38%
AVERAGE	24%
Bad	17%

3.1 Functional Results Depending on Therapeutic Modalities

The results were excellent and good in:

60% of patients treated with internal osteosynthesis.

30% of patients treated by external osteosynthesis.

10% of patients treated with combined treatment.

3.2 Radiological Results

The criteria described by Arlettaz [4] allowed us to collect our results; In our study, the results are as follows:

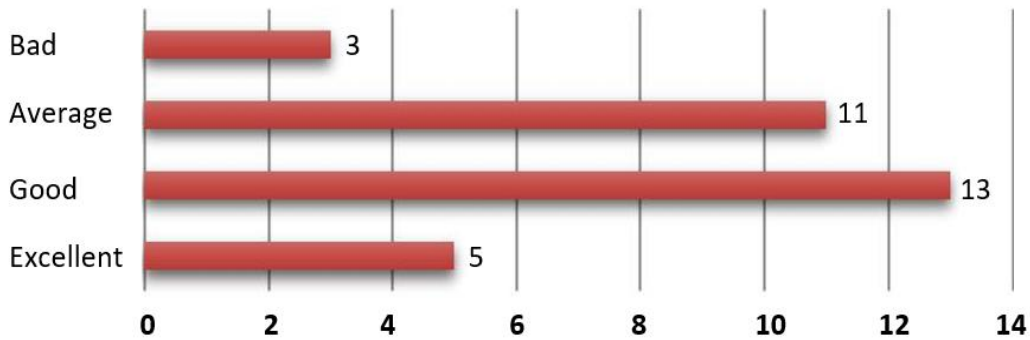


Fig. 5. The quality of radiological reduction in our patients

4. DISCUSSION

The use of the term "Pilon Tibial" comes from Etienne DESTOT in 1911 in his work on radiological description of foot fractures [5]. The term Pilon came about through the resemblance of the shape of the distal tibia to a drumstick.

According to BourneArlettaz and Evan [4,6,7] they represent 7% of tibia fractures and 1% of lower limb fractures. Decoulx, Razemon, Rousselle [8] grouped 13.7% of tibial pilon fractures out of 350 cases of instep fractures.

In these different series [4,9,10], the average age varies between 38 and 45 years. In our study, the age group between 40-49 years old Which corresponds to the active population, as well as the predominance of accidents on public roads.

In our series we observe a clear male predominance with 68% men for 32% of women; i.e. a sex ratio of 2 (2.2 vs 1). Which is consistent with the literature [4,11,12,13,14].

Male exposure to violent trauma is linked to professional activity and extensive practice of contact sports which may explain this particularity.

Most cases of fracture in our study result from a high-energy injury mechanism. The etiologies were dominated by: a fall from a high place,

public road accidents and road accidents. This remark is consistent with that of several authors [15,16].

Skin lesions associated with this fracture are considered an important early and secondary risk factor, following the precarious cutaneous vascularization of this region. In our series [17,18,19,20]. Closed fractures were most frequent in our study which was same as in previous studies.

Radiologically; the frontal and lateral views centered on the tibioastragal space are sufficient to make the diagnosis of tibial pilon fracture and obtain an anatomo-radiological classification.

Other complementary incidences may prove useful such as the frontal incidence in external rotation at 10° of the foot which better clears the ceiling of the mortise and the tibio-talar space, as well as the 3/4 incidence which allows us to identify the superposition of the fracture lines with the fibula.

Computed tomography is of interest for the evaluation and classification of fractures which are difficult to study using standard radiography, as well as for the preoperative planning of surgical treatment [21,22]. It makes it possible to choose the approach to adopt., through the measurement of the fracture angle formed by the axetibio-fibular and the majority fracture line:

Table 6. Distribution of cases according to skin opening

Authors	Closed fractures (%)	Open fractures (%)
Leung [17]	81	19
Bacon [18]	54	46
Babis [19]	72	28
Manca [20]	73	27
Our study	80	20

The incision must be lateral if the fracture angle is $< 90^\circ$.

The incision must be antero-internal, if the fracture angle is $>90^\circ$.

The use of MRI is reserved for the evaluation of ligamentous and other soft tissue injuries, which are often associated with malleolar fractures [23].

Numerous classification systems have been developed since the 1960s [2].

At the end of the 1960s, the classification of Rûedi and Allgöwer was the most recognized internationally for these lesions [24,25].

A new classification was developed at the 1991 symposium of the French Society of Orthopedic Surgery and Traumatology (SOFcot) for tibial pilon fractures [3], based on the work of Vives and Hourlier; as well as the analysis of Gay and Evrard.

In our series, we adopted the latter, because it allowed us to conclude the rate: fractures with incomplete metaphyseal rupture including 40.5% and fractures with complete metaphyseal rupture including 59.5%.

According to the literature, whatever the classification used: the rate of fractures with complete metaphyseal rupture is higher than that of fractures with incomplete metaphyseal rupture [4,26].

The management of tibial pilon fractures must be an immediate emergency, otherwise it is a delayed emergency following several reasons:

Post-traumatic edema which causes the skin to suffer;

The importance of comminution;

The poor condition of the soft parts due to skin damage or even to an opening by the large fracture displacement.

The operating time should not exceed 8 to 12 hours; otherwise, it is preferable to postpone the operation 7 to 10 days later while waiting for improvement in the skin condition [27].

Concerning the approach; It is necessary to remember that there is no muscular insertion on the tibial pilon as on the talus, which makes its vascularization fragile. Some basic notions in the choice of surgical approach [28]:

Center the incision on the largest or most displaced fragment, because its exact reduction conditions the entire epiphyseal reconstruction.

Avoid traumatizing the skin with aggressive retractors, it is therefore necessary to make large incisions allowing good exposure.

Respect a minimum distance of 6cm between two vertical incisions Arthrotomy is essential to monitor the cartilaginous surfaces.

the anteromedial route is the most used in our training with a rate of 58%. This route has been adopted by several authors such as: HEIM [29], ARLETTAZ [4] and HELFET [9] followed by the anterolateral route with a rate of 33%.

The most commonly used internal osteosynthesis material is the cloverleaf or anatomical plate. Other plates can be used such as: the thin 'T' plate, L plate, posterior console plate particularly in partial fractures or isolated compressive screwing.

Nailing is limited to type 43A and C1 fractures according to AO classification. It should also be noted that fractures containing a displaced split of the anterior margin of the tibia are excluded from treatment by nailing. Skin closure is the most important part of the procedure, because it is essential to avoid any tension and perfectly suture vital skin. According to Leone [30], to close the operating wound; it is necessary to start first with the tibial route, then the fibular route for two reasons:

1. Cover the tibial osteosynthesis material.
2. Avoid the occurrence of secondary skin necrosis: since the skin at this stage is thin, fragile and poorly vascularized.

Other authors say that:

- if the two operating wounds are well bleeding and possible to be closed without tension, we will consider the primary closure of the 2 routes
- if there are skin lesions with a questionable vascular state of the surgical wounds: the tibial approach must first be closed, then the subcutaneous tissue should be brought closer to the peroneal approach, leaving the skin for directed healing [31].

In our study, the external fixator was used in 25% of cases for complex fractures where the skin

condition and the type of fracture did not allow the use of internal osteosynthesis or traction. According to Babis

[19], external fixation presents less risk of complications.

The objective of minimally invasive surgery is: the reduction and stabilization of the fracture site with a result approximately equivalent to that obtained with the approach to the fracture site; while reducing surgical aggression. This technique is aimed at minimally displaced fractures; without joint/metaphyseal comminution.

Arthrodesis also finds its place in fractures with significant joint damage and the association with cartilaginous lesions of the talus makes any reconstruction impossible. Furthermore, there is never an emergency to carry out an arthrodesis, if the indication is made; this can be carried out remotely in better conditions in the absence of soft tissue pain.

The risk of secondary complications is present, as with any surgery, of which infection comes first. It can be increased due to the fact that the skin of the leg is fragile, the bone is under the skin.

These complications have an impact on short- and long-term functional results.

5. CONCLUSION

In the light of our retrospective study, which focused on a series of 54 cases treated surgically, we note the seriousness of these fractures, as long as they affect the long-term functional prognosis; and still remain a real challenge for the surgeon.

CONSENT

Written informed consent was obtained from the patients for publication and any accompanying images.

ETHICAL APPROVAL

It is not applicable.

DISCLAIMER (ARTIFICIAL INTELLIGENCE)

Author(s) hereby declare that NO generative AI technologies such as Large Language Models (ChatGPT, COPILOT, etc) and text-to-image generators have been used during writing or editing of this manuscript.

COMPETING INTERESTS

Authors have declared that no competing interests exist.

REFERENCES

1. Mauffrey C, Vasario G, Battiston B, Lewis C, Beazley J, Seligson D. Tibial pilon fractures: A review of incidence, diagnosis, treatment, and complications. *Acta Orthop Belg.* 2011; 77:432–440.
2. Copin G, Nerot C. Fractures of the tibial pilon in adults. *Rev Chir Orthop.* 1992;78:33-83. (SOFcot Symposium. Paris, November 1991).
3. Nerot C, Tozzini JP. Recent fractures of the tibial pilon in adults. Update of anatomoradiological data and presentation of the series. Classification of tibial pilon fractures. *Rev Chir Orthop.* 1992; 78 :36 - 45.
4. Arlettaz Y, Blanc CH, Chevalley F. Fractures of the tibial pilon. Long-term retrospective study of 51 fractures treated by bloody reduction and osteosynthesis. *Rev Chir Orthop.* 1998; 84:180-188.
5. Destot E. Foot trauma and X-rays. Masson; 1911.
6. Bourne RB. Pilon fractures of the distal tibia. *Clin Orthop.* 1989;240:42-46.
7. Evan H, Karas, Lons Weiner. Displaced pilon fractures. *Orthop. Clin. North America.* 1994;25(4).
8. Alexandre and Mathieu L. Assessment and classification of fractures of the tibial pilon. *ROC Ecole du val-de-Grace.* 2010 Sep 25. RV. 2011 Wednesday January 12.
9. Borrelli J Jr, Ellis E. Pilon fractures: Assessment and treatment. *Orthop Clin North Am.* 2002 Jan; 33(1):231 -45.
10. Biga N, Laurent M, Alain J, Thomine JM. Prognostic factors, scalability, radio-clinical correlation and tolerance of malunions. *Rev Chir Orthop.* 1992; 78.SOFcot, 66 annual meeting.
11. Nicandri GT, Dunbar RP, Wahl CJ. Are evidence-based protocols which identify vascular injury associated with knee dislocation underutilized? *Knee Surg Sports Traumatol Arthrosc.* 2010;18:1005–1012.
12. Helfet D, Kennet K, Pappas J. Intra-articular pilon fractures of the tibia. *Clin Orthop Related Research.* 1994; 298:221-228.
13. Kao KF, Huang PL, Chen YW, Lin SY, Ko SH. Postero-medio-anterior approach of

- the ankle for the pilon fracture. *Injustice*. 2000; 31:71-4.
14. Arzaz M. Fracture of the tibial pilon, experience of the orthopedic traumatology service, concerning 25 cases at the Moulay Smail hospital in MEKNES. *Med Thesis Rabat*. 2005 :185.
 15. McCann PA, Jackson M, Mitchell ST, Atkins RM. Complications of definitive open reduction and internal fixation of pilon fractures of the distal tibia. *Int Orthop*. 2011;35: 413–8.
 16. Liporace FA, Yoon RS. Decisions and staging leading to definitive open management of pilon fractures: Where we come from and where are we now? *J Orthop Trauma*. 2012;26:488-98.
 17. Leung F, Kwok HY, Pun ST, Chow SP. Limited open reduction and Ilizarov external fixation in the treatment of distal tibial fractures. *Injury*. 2004; 35(3):278-83.
 18. Bacon S, Smith WR, Morgan SJ, Hasenboehler E, Philips G, Williams A, et al. A retrospective analysis of comminuted intra - articular fractures of the tibial ceiling: Open reduction and internal fixation versus external Ilizarov fixation. *Injury*. 2008; 39:196–202.
 19. Babis GC, Kontovazenitis P, Evangelopoulos DS, Tsailas P, Nikolopoulos K, Soucacos PN. Distal tibial fractures treated with hybrid external fixation. *Injury Int. J. Care Injured*. 2010; 41: 253-258.
 20. Manca M, Marchetti S, Restuccia J, Faldini A, Faldini C, Giannini S. Combined percutaneous internal and external fixation of type C tibial ceiling fractures. *J Bone Joint Surg Am*. 2003 May; 85 -A (5): 912.
 21. Biga N, Laurent M, Alain J, Thomine JM. Prognostic factors, scalability, radio-clinical correlation and tolerance of malunions. *Rev Chir Orthop*. 1992:78. SOFCOT, 66 annual meeting.
 22. Coudert B, Raphael M. Recent ankle trauma. *EMC, emergency medicine*. 2007;25(200):30.
 23. Othmane Bouyalitene. Bimalleolar fracture. *Thesis Casablanca*. 2003:126.
 24. Decoux P, Razemon JP, Rousselle Y. Pilon tibial fractures. *Rev Chir Orthop*. 1961;47:563-577.
 25. Rüedi T, Matter P, Allgöwer M. Die intraartikulären Fracturen des distalen Unterschenkendes. *Helv Chir Acta*. 1968; 35:556-82.
 26. Benchakroun M, Ismael F, Yacoubi H, et al. Fractures of the tibial pilon about 30 cases. *Medicine and Armies*. 2003; 31(2):113-120.
 27. Brumback RJ, William C, MC Garvey. Fractures of tibial ceiling; evolving treatment concepts for the pilon fractures. *Orthop. Clin. North Am*. 1995; 26: 2.
 28. Plaweski S, Huboud-Peron A, Faure C, Merloz P. Fractures of the tibial pilon. *Medical-surgical encyclopedia (Elsevier, Paris), Musculoskeletal system*, 14-087-A10, 1999-Podiatry. 1999:13.
 29. Heim U. Fractures of the tibial pilon. *SOFCOT teaching notebooks*. 1997: 35 - 51.
 30. Leone V, Robert R. The management of the soft tissue in pilon fractures. *Clin Orthop Related Research*. 1993; 292:315-320.
 31. Bour P, Aubry P, Fieve G. Vascularization of the tibial pilon. *Therapeutic applications. Rev. Chir. Orthop*. 1992:78. SOFCOT, 66th Annual Meeting.

Disclaimer/Publisher's Note: The statements, opinions and data contained in all publications are solely those of the individual author(s) and contributor(s) and not of the publisher and/or the editor(s). This publisher and/or the editor(s) disclaim responsibility for any injury to people or property resulting from any ideas, methods, instructions or products referred to in the content.

© Copyright (2024): Author(s). The licensee is the journal publisher. This is an Open Access article distributed under the terms of the Creative Commons Attribution License (<http://creativecommons.org/licenses/by/4.0>), which permits unrestricted use, distribution, and reproduction in any medium, provided the original work is properly cited.

Peer-review history:
The peer review history for this paper can be accessed here:
<https://prh.ikpress.org/review-history/12628>